# Histological and Morphological Studies of digestive tube and liver of the Persian tooth-carp, *Aphanius persicus* (Actinopterygii: Cyprinodontidae)

Malihezaman Monsefi[1*], Zeinab Gholami[2], Hamid-Reza Esmaeili[1]
[1]*Biology Department, College of Sciences, Shiraz University, Shiraz 71454, Iran*
[2]*Islamic Azad University, Babol Branch, Veterinary Mdicine Department, Mazandoran, Iran*

## Abstract

Histology offers a powerful tool in the study of detailed structures of different tissues in fishes. It is used for sex verification, identifying stages of development, presence of parasites, tumors diagnosis, other abnormalities and changes in the arrangement of tissue layers including the digestive tract. In this study, not having found any existing report, the digestive tract histology of the Persian tooth-carp, *Aphanius persicus* (Jenkins, 1910), was investigated. The dentition comprised canine-like teeth in one row with sharp tips. Esophagus consisted of small portion between pharynx and stomach. Stomach showed an enlargement and the intestine is relatively short. The mucosa of total digestive tube consisted of simple columnar cells and numerous goblet cells. The liver is composed of parenchymal cells and lattice fibers whose function is to support the former. Our data showed this fish is heterodont, omnivores with no secretory stomach.

**Key words**: Persian tooth-carp, *Aphanius persicus,* digestive tract, histology.
***Corresponding author:** Monsefi Malihezaman (E-mail: monsefi@susc.ac.ir)
(Received: 03.04.2009 Accepted: 15.06.2009)

## Introduction

The alimentary canal of teleostean fishes has been widely studied and described morphologically to determine the function of many specialized anatomical structures in relation to the different feeding adaptation of this large group (Catladi et al. 1987). No report can be found on the histology of *A. persicus*. This study examines the structure of digestive tract of Persian tooth-carp, *A. persicus* with a view to the understanding of physiological alternation and probable pathological changes. *A. persicus* (Jenkins 1910) is an endemic cyprinodontid fish species from Maharlu lake basin, Fars province, southern Iran (Esmaeili and Shiva 2006; Coad 1996; Coad and Abdoli 2000). Maharlu Lake is situated at an altitude of about 1460 meter. It is a chloride and fishless lake. This tooth-carp is found in tributary streams and springs around the lake. This small fish species (maximum is 5 cm) is one of the valuable fresh water fishes because of its use in the control of malaria and also in the aquarium trade. It feeds on copepods, diatoms, cyanobacteria, green algae and some insects. Its tooth shape is tricuspid, conical with sharp tips in one row on upper and lower jaws. The length of digestive tract is relatively short. The histological and histochemical characteristics of the mucosubstance from the esophagus of freshwater teleosts have been investigated (Meister et al. 1983; Eastman and DeVries, 1997; Diaz et al. 2006) but we did not find any report about *A. persicus.* Therefore the aim of the present study was to give a really detailed description of the Persian tooth-carp digestive tube and liver histology and to give data on this fish and provide conditions for the conservation of this small and colorful fish.

## Materials and methods

Four specimens of Persian tooth-carp with body weight 1.219-3.550 gram and total length 41.1-54.9 mm were collected from the spring system near Maharlu Lake (52°, 43´N, 29°, 27´E) by dip net. Fishes were killed by a stroke to the head. The body cavity was opened and the entire digestive tract from the mouth to the anus was removed and immediately fixed in Bouin's solution. The total length of the separated digestive tube was 26.9-38.4 mm. The digestive tube was divided into seven parts including the roof of the mouth, the outer end of the esophagus, the first portion of the stomach and five areas of the intestine. The first 1/5 intestinal portion was selected immediately after the stomach and the second to fifth portions were removed each 0.5-0.7 mm from each other respectively. After fixation each portion of digestive tube was dehydrated in a series of 80, 96 and 100 % ethanol solutions. Then the tissues were cleared in 2 changes of xylol solution and impregnated and embedded in paraffin. The tissue blocks were sectioned by rotary microtome (Spencer 820, U.S.A). The 5-7 micrometer thickness of the transverse sections of different parts of the digestive tube and a longitudinal section of the full digestive system were stained with hematoxline and eosin for light microscopy examination (Bancroft and Stevens 1991). The diameter of the different parts of each section were measured by ocular micrometer device (Carl Zeiss West Germany) with 0.01 mm accuracy using light microscope (Zeiss, West Germany). The photographs were taken by digital camera (Canon Eos Digital, Japan) fixed on light microscope.

## Results

The length of the digestive tract from mouth cavity to abdominal anal portion was 36.1mm. The length of mouth cavity and pharynx of the Persian tooth-carp measured 9.6 mm and the rest of the digestive tract or opened digestive tube from esophagus to anus was 26.5mm (Fig. 1). That is relatively short and approximately 97.5 % of the standard body length.




**Figure 1.** The shape and length of in situ (A) and opened (B)digestive tube of Persian tooth-carp, *Aphanius persicus.* Gonad (G), intestinal loop (I), stomach (S) and liver (L).

The oral cavity covered stratified squamous epithelium with numerous taste cells (Fig. 2).

Teeth appeared in upper and lower jaws and pharyngeal region. Jaw dentition is composed of tricuspid, small canine teeth lined in one row with sharp tips. There are 17-18 tricuspids teeth in the upper jaw and 18-20 teeth in the lower jaw (Fig. 3). Pharyngeal teeth consist of three parts: two parts in the roof of the mouth and the other one in the bottom of the mouth. In the floor of the oral cavity, there is a triangular bone that has7-8 relatively irregular rows of bicuspid teeth arranged on it. This bone consisted of 22-26 teeth in its base, 4-6 teeth in the tip, 6-7 teeth in the medial border and 13-18 teeth in the lateral border. The largest teeth are in the base of this triangular bone (Fig. 4). The roof pharyngeal bone consists of 2 oval shape bones that join together with connective tissue. There are 5-7 rows of teeth on these bones and their arrangement included: 6-7 teeth at the base, 6-10 teeth in the tip, 5-6 teeth in the medial and lateral borders (Fig. 4). The movement of these parts all together cause food fragmentation.

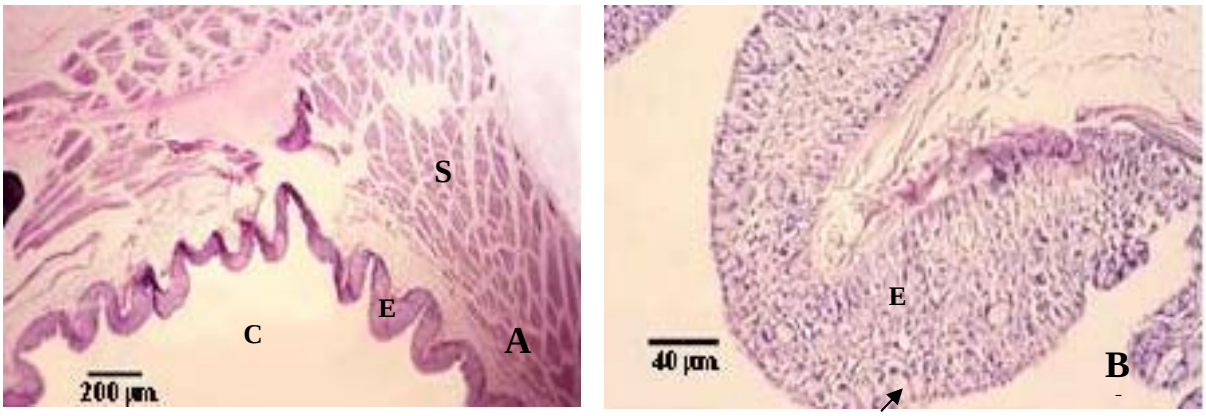


**Figure 2.** Photograph of mount cavity of Persian tooth-carp, *Aphanius persicus* (A), high magnification of its epithelial tissue (B). Hematoxyline & eosin staining. Epithelium (E), roof mouth cavity (C), striated muscle (S), Taste bud (small arrow).

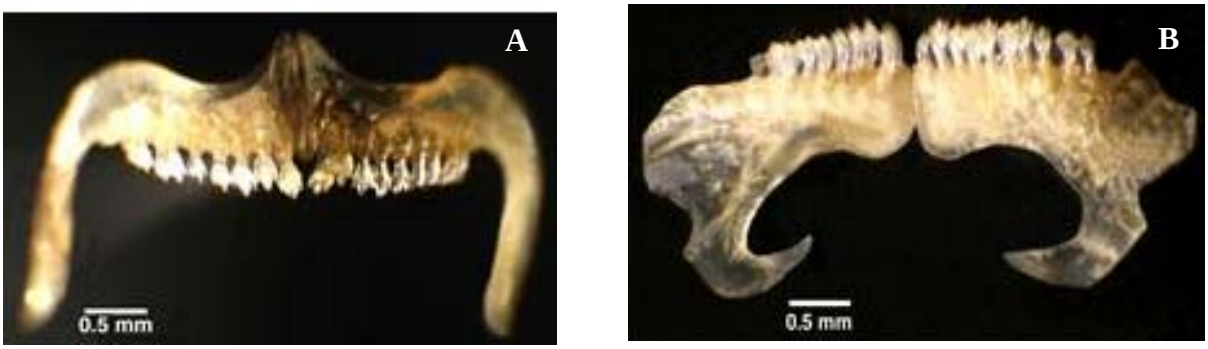


**Figure 3.** The seprated jaw dentition of Persian tooth-carp, *Aphanius persicus.* The anterior view of upper jaw (A) and lower jaw (B).

Figure 1 shows in situ the alimentary canal after dissection. The histological study reveals that the digestive tube wall is composed of several layers: mucosa, submucosa, muscularis and serosa. The mucosa consists of the epithelium and lamina propria. The first part of the digestive , the esophagus, immediately after the pharynx, has 0.7 mm diameter and 1.5 mm length. At its outer end the mucosa consists of numerous villi that show simple high columnar epithelium with numerous goblet cells. The lamina propria of this part consisted of loose connective tissue with some regular and parallel fibers of striated muscles in the core of villi (Fig. 5B). The thin submucosal layer consists of loose connective tissue. The muscular layer from inside to outside of the esophagus formed thick circular striated muscle and a longitudinal arrangement of very thin smooth muscle.

The first part of the stomach consists of a dilated tube, 1.7 mm in diameter and 5.3 mm in length after the small constriction of the esophagus. It is covered with simple columnar epithelium in villi and short simple branch tubular glands. Lamina propria and circular and longitudinal smooth muscle layers can be seen (Fig. 5A). There are some goblet cells but no other secretory cells (such as parietal or acid secretion cells) among the columnar cells.

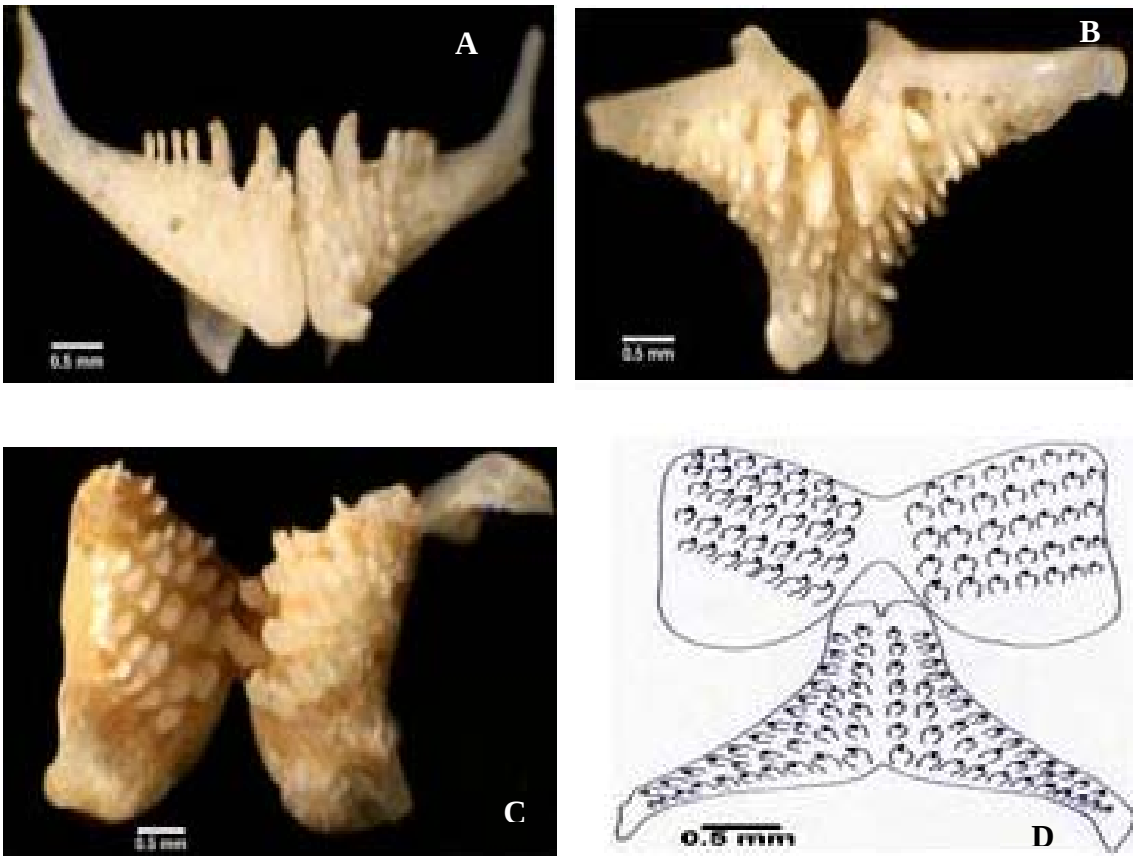


**Figure 4**. The seprated pharyngeal dentition of Persian tooth-carp, *Aphanius persicus.* The teeth of pharyngeal bone in floor of oral cavity; anterior view (A) and posterior view (B); the teeth of pharyngeal bone in roof of oral cavity (C); diagram of pharyngeal teeth (D).

The intestine was long and thin with 0.8-0.9 mm diameter that was histologically uniform except for the hindmost section separated from the central part with intestinal mucosa developed longitudinal folds and very high villi. This was longer than in the anterior section. In the mid parts of the intestine, villi are short, regular and flat. The mucosal epithelium of the entire intestine contained simple columnar with goblet cells. The number of goblet cells increased from the first to the endmost part of the intestine (Fig. 6). The mid part of the intestine shows the thick circular smooth muscle that constricted its lumen. It probably acts as a sphincter (Fig. 7).

The lamina propria of the digestive tube, especially in the foremost part, consisted of considerable solitary lymphoid tissue and inflamed eosinophilic cell (Figs. 7 and 8). These inflammations and high vascular tissues were seen around the sections of worms that penetrated in the the wall of intestine (Figs. 8).

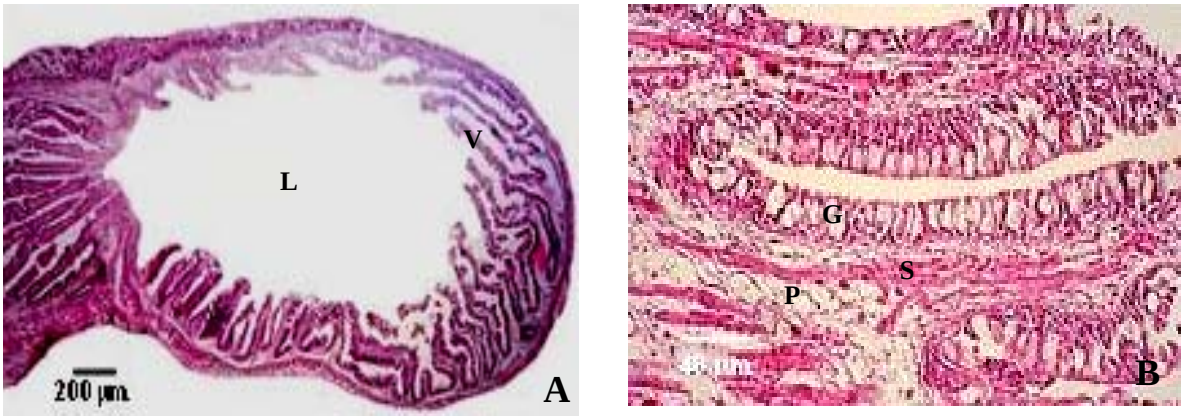


**Figure 5.** The first portion of digestive tube of Persian tooth-carp, *Aphanius persicus*. The outer part of esophagus (left side) and the first portion of stomach (right side) see in A photograph and High magnification of esophageal part in B photograph. Please note abundant goblet cell and striated muscle in the core of esophageal villi. Hematoxiline and eosin staining. Lumen of stomach (L), villous (V), goblet cell (G), striated muscle (S), lamina propria (P).

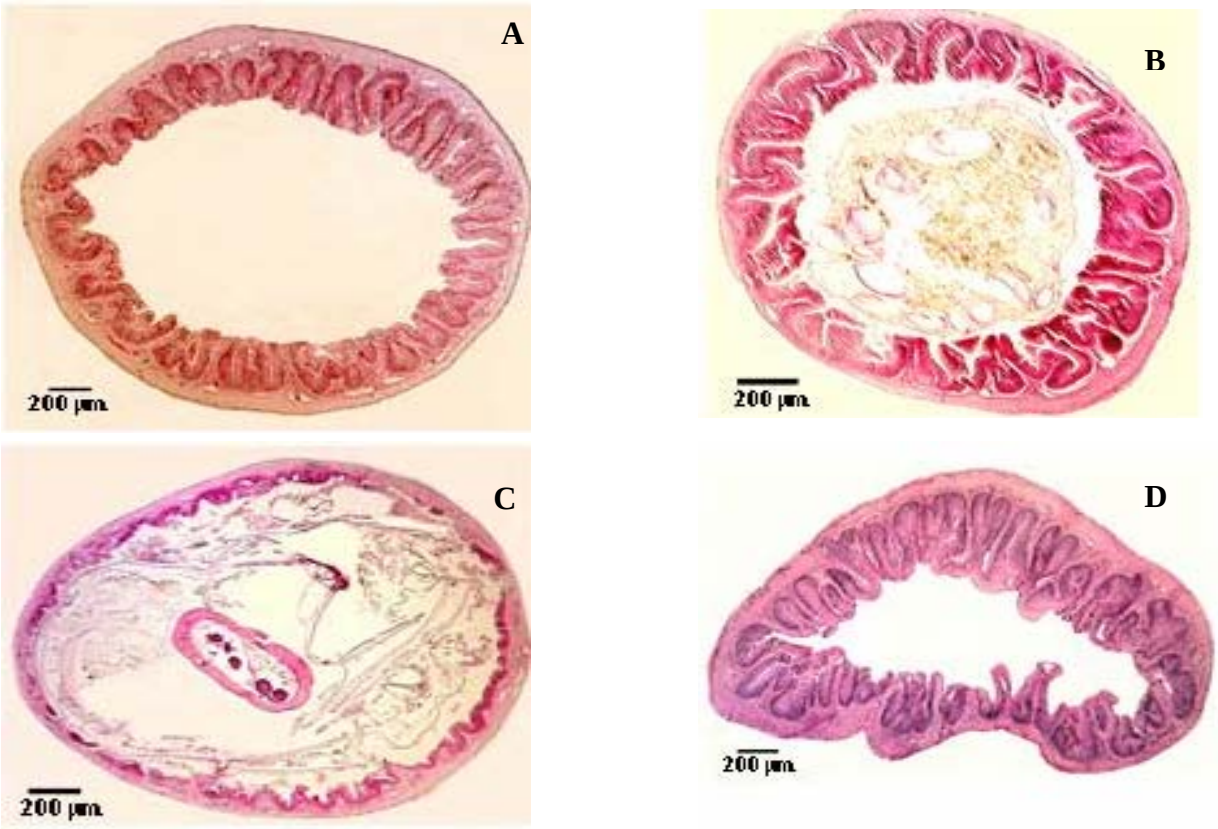


**Figure 6.** The transverse sections of different portions of intestinal part of digestive tube of Persian tooth-carp, *Aphanius persicus.* First portion after stomach (A), second portion (B), mid portion (C) and hind most portion (D).

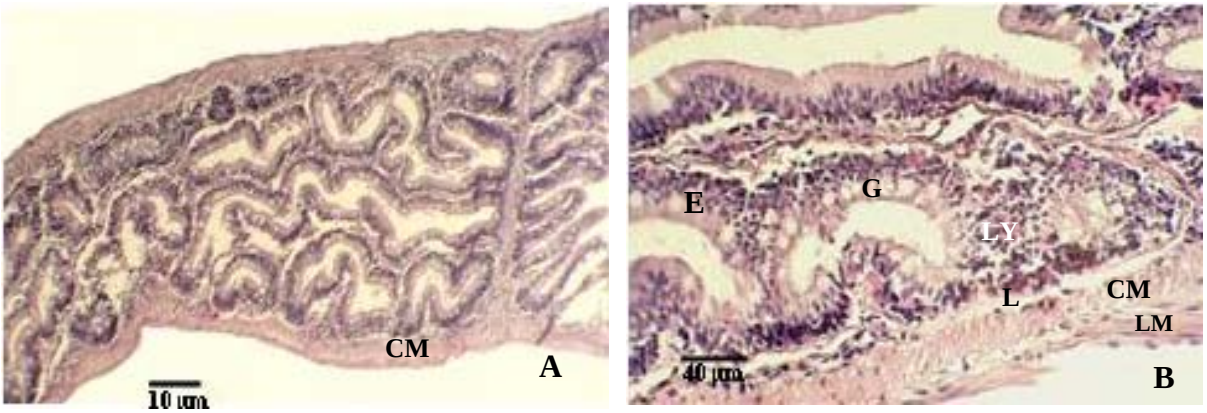


**Figure 7.** The longitudinal sections of intestine of Persian tooth-carp, *Aphanius persicus* (A); and its high magnification (B). Epithelium (E), lamina propria (L), goblet cell (G), circular muscular layer (CM), longitudinal muscular layer (LM) and lymphoid tissue (LY).

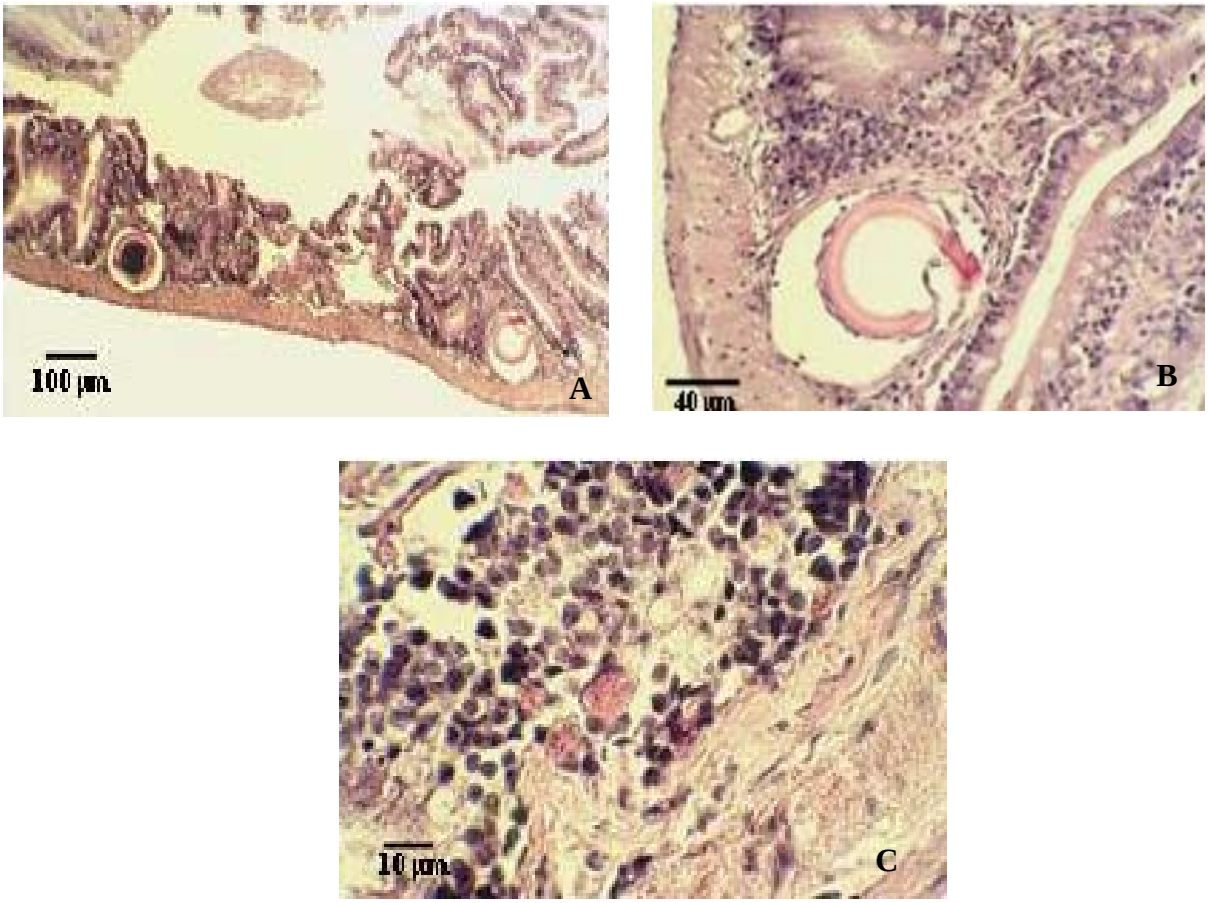


**Figure 8.** The penetrated parasites into the wall of digestive tube of Persian tooth-carp, *Aphanius persicus* (A); its high magnification (B), the inflamed cells of lamina propria around polluted area (C). Hematoxyline and eosine staining.

The U shaped liver is the largest of accessory glands of the digestive system. It is centrally located in the peritoneal cavity, ventrally to the esophagus and anterior-ventrally from the stomach. The color is light brown. The parenchyma itself is primarily composed of polyhedral hepatocytes with radial arrangement typically with central nuclei. Vacuolization of hepatocytes resulting from glycogen and/or fat storage can produce considerable histological variability. Sinusoids arranged between hepatocytes and covered with simple squamous epithelium. Adjacent sinusoids are separated from one another by two hepatocytes. In the case of vacuolization, the nuclei and hepatocytes are compressed eccentrically toward the sinusoidal spaces. Bile ducts also occur within the parenchyma of the liver. Smaller ducts within the liver were covered with a single layer of cuboidal epithelial cells (Fig. 9).

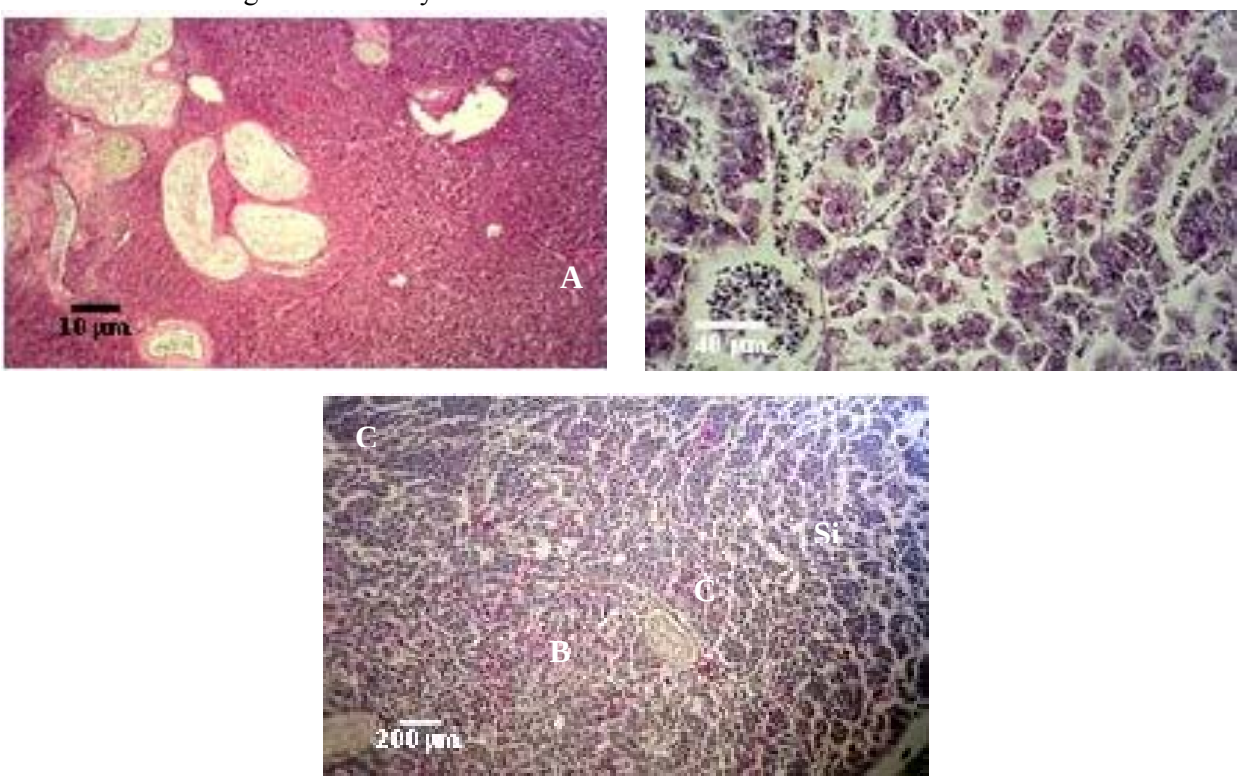


**Figure 9.** Liver of Persian tooth-carp, *Aphanius persicus* (A); its high magnification (B and C). hematoxyline and eosine staining. hepatocyte (H), sinusoids (Si), central vein (C).

## Discussion

The feeding mode and food type are associated with the body form and digestive apparatus. A tremendous diversity exists in the form and size of fish teeth. The character of the dentition is a clue to the fish's feeding habits and the kind of food it consumes. This species has small sharp, conical tooth in one row. This type of teeth does a good job of grasping and piercing. This species also has teeth in its throats. These sharp pharyngeal teeth oriented in the back or to the pharynx and facilitated food movement to the digestive tube. The shape and size of these teeth differed from jaws teeth therefore this fish is known as heterodont. According to our data and on the basis of digestion food analysis, this fish is classified as omnivores but their characters are the same as to carnivores fishes. In contrast to herbivorous species that feed on detritus and algae,

carnivorous and omnivores species tend to have shorter gut lengths. The A. *persicus* have a short gut and its gut length relative to standard length had the value 0.95-0.38 that conformed with Kramer and Bryant (1995) report. They had measured 0.7-0.9 of this value for carnivores' species, 1.1-2.2 for omnivores and 5.4-28.7 for herbivores. A very short esophagus dilated immediately and formed stomach for food perseverance. The remaining part of the digestive tube consisted of an intestine that showed the same diameter. The histological structures of digestive tube were similar and consisted of simple columnar epithelium with goblet cell. The number of goblet cells was different. The high density of these cells in the posterior intestine is essential for easy defecation. There is no secretory stomach with gastric gland and no different area such as cardia or pylorous portion. Digestion in fishes by enzymatic and acidic secretions in the gut attests to the variety of morphological and chemical adaptations of the digestive tube. The absorption of nutrients across fish intestinal walls closely parallels the process of mucosal intestinal surface. Therefore, despite the similarity of histological structure, it may be understood that the enzymatic activity of columnar cells accompanied with pancreas and liver secretion assisted food digestion in *A. persicus.* The large gall bladder, situated between the liver and anterior intestine, confirmed the high activity in the liver of this fish.

There is an abundance of solitary lymphatic tissue in the digestive tube of this fish. This tissue, aggregated around many parasites that enter this system via nutrient or water,ensures that *A. persicus* can live and survive in a pollutant water environment.

**Acknowledgement**

This study was financially supported by the Office of Vice-Chancellor for Research of Shiraz University.

**References**

Bancroft J.D. and Stevens A. (1990) Theory and practice of histological Techniques. Churchill Living stone, New York, USA.

Catladi E., Cataudella S., Monaco G., Rossi A and Tancioni L. (1987) A study of the histology and morphology of the digestive tract of the sea-bream, *Sparus aurata*. *Journal of Fish Biology,* 30: 135-45.

Coad B.W. (1996) Systematics of the tooth-carp genus *Aphanius* Nardo, 1827 (Actinopterygii: Cyprinodontidae) in Fars Province, southern Iran. *Biologia*, *Bratislava,* 51(2): 163-72.

Coad B.W. and Abdoli A. (2000) Systematics of an isolated population of tooth-carp from northern Iran (Actinopterygii: Cyprinodontidae). *Zoology in the Middle East,* 21: 87-102.

Diaz A.O., Escalante A.H., Garcia A.M. and Goldemberge A.L. (2006) Histology and Histochemistry of the pharyngeal cavity and oesophagus of the silverside *Odontesthes bonariensis* (Cuvier and Valenciennes). *Anatomy Histology Embryology,* 35:42-46.

Esmaeili H.R. and Shiva A.H. (2006) Reproductive Biology of the Persian tooth-carp, *Aphanius persicus* (Jenkis, 1910) (Cyprinodontidae) in southern Iran. *Zoology in the Middle East,* 37: 39-46.

Eastman J.T. and DeVries A.L. (1997). Morphology of the digestive system of *Antarctic nototheniid* fishes. Polar Biology, 17:1-13.

Kramer O.L. and Bryant M.J. (1995) Intestine length in the fishes of a tropical stream: 1. ontogenetic allometry. *Environmental Biology of Fish,* 42**:** 115-27.

Meister M.F. Humbert W., Kirsch R. and Vivian-Roels B. (1983). Structur and ultrastructure of oesophagus in sea- water and fresh-water teleosts (pisces). Zoomorphology, 102: 33-51.